Upper Motor Neuron Lesion

Leukodystrophies degeneration of white matter in Brain. Imperfect growth or development of myelin sheath
Sx: ↓motor function, muscle rigidity, ↓sight and hearing

Metachromic Leukodystrophy Arylsulfatase-A def.

Krabbes Dx - Galactocerebrosidase β-galactosidase def. Death 2 years

Adrenoleukodystrophy inability to catabolize very long F.A.

Brain Mass

U.T. B12 def

Vasculitis

UMNL
DTR = ↑
muscle tone - ↑
Fasciculations = absent
superficial reflex = absent
clonus = present
atrophy = absent

Guillane-Barre

EXAM
ascending weakness, loss of reflexes, Sensory loss

Peripheral Nerves

Sx 1st - Dysesthesia (abnormal sensation) paresthesia of hands feet, (Kiss-Gait)
2nd Pain back, ileus, urinary retention respiratory muscle paralysis (10-30%)

Why? URI or diarrhea 1-3 weeks prior (50-70%) CMV, vaccine
Demyelinating Dx of Peripheral Nerves (Schwann cells), Ascending Paralysis

Dx Nerve conduction Test - F-wave latency (most specific). CSF (↑protein ↑ nml cell count) leads to papilledema.

Tx mechanical ventilation, Immunoglobulin, plasmapheresis

Note: 5% of pts die

Lead Poisoning Damages (fractures) more motor nerves than sensory.

Arsenic can mimic Guillen-Barre

also constipation, anemia
Tx: EDTA or Succimer
if severe: EDTA + Dimercaprol

Diabetic Neuropathy - Lyrica, Gabapentin

also
- Microvascular injury
- Glycosylation
- Protein Kinase C (from ↑ diacylglycerol)
- Sorbitol aldose reductase

Neuromuscular Junction Disorders

EXAM
Sensory = nml
DTR = nml
nml pupillary response

Myasthenia Gravis 1:25K

Sx: Progressive muscle weakness, Diplopia, difficulty chewing/swallowing. Fatigue after exertion, incontinence
Muscle weakness w/o sensory or DTR Δ's

Why? Post-Synaptic defect
antibody to Acetylcholine Receptor (AchR)

Dx Tensilon Test (Edrophonium) or Anti-achR antibodies in serum 90%

Tx anti AchE drugs (Pyridostigmine) plasmapheresis corticosteroids IVIG Thymectomy

Note: Give medication strict schedule (ie. 30 min before meals b/c quick in quick out - choking.

↑respiratory muscle ↓ HTN incontinence > Myasthenic Crisis (Too little med or too late)
vs
muscle twitching Cholinergic Crisis (Too much medication) "Inhibitor" to the point of weakness. Abdominal Pain

Anterior Horn Cells

motor neurons that affect axial muscles

Amyotrophic Lateral Sclerosis
Stiff muscles, muscle twitching worsening muscle wasting ↓speaking, swallowing and eventually breathing
"Death of neurons of voluntary muscles"
Tx: Riluzole

Paraneoplastic Syndromes
Triggered from auto immune response to neoplasm. usually site distal to tumor/cancer

Poliomyelitis Fecal-oral route, Replicates in Oropharynx and small intestine before spreading through bloodstream to the CNS where it leads to destruction of Ant. Horn cells (LMN).
Sx: Malaise, Fever, Nausea, muscle weakness, atrophy, Fasciculations, hyporeflexia
CSF: lymphocyte pleocytosis, ↑ protein, nml CSF glucose
Virus recovered from stool or throat.

Werdnig Hoffman Dx AR inheritance
"Floppy Baby at Birth" Tongue Fasciculations
LMN involvement only. Median age of Death is 7 months.

LAMBERT-EATON Syndrome

Sx proximal muscle weakness that improves with use. Dry mouth, impotence
Tend to improve with use

Why? Pre-Synaptic Defect, antibodies target pre-synaptic terminal → ↓Ca^{2+} channels therefore fewer Ach released.

EXAM
↓DTR
nml Sensory
look for anti-VGCC antibodies in blood

Dx repeated Nerve stimulation
↓response during Steady state stimulation
↑↑ response to tetanic Stimulation

Tx 3,4-Diaminopyridine (Blocks outward K^+ from presynaptic term. ↑Ca^{2+} influx, Voltage Gated Calcium channel stay open longer.

VGCC - voltage gated calcium channel

Note: LES precedes Cancer in 80% cases

Hypothyroid

impaired carbohydrate synthesis, ↓protein turnover affects muscle.

Corticosteroids see below

Muscle Fibers

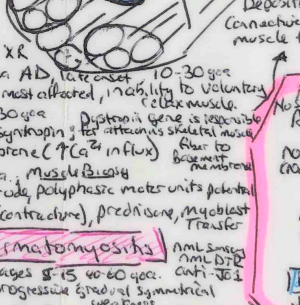

Deposits of Fat and Connective tissue replace muscle fibers, the muscle undergoes necrosis

Muscular Dystrophies FH of muscle Disease progressive muscle disorders.

2MC
Duchenes MD - absence of Dystrophin, XR (Affects boys)
1:3500
Becker's MD - insufficient Dystrophin XR

Fascioscapulohumeral MD, onset < 20 yrs AD, late onset 10-30 yrs
Myotonic MD - AD - Face and Hands most affected, inability to voluntary relax muscle.
Limb Girdle - AR, late onset, 10-30 yrs

Why? Dystrophin interacts with actin, syntrophin; affects integrity of plasma membrane (↑Ca^{2+} influx)
Dystrophin gene is responsible for attaching skeletal muscle fiber to basement membrane

Dx Creatine Kinase ↑ 50-100x by 3 yrs. Muscle Biopsy
EMG - short duration, low amplitude, polyphasic motor units potential

Tx Physical therapy, braces, surgery (contracture), prednisone, Myoblast Transfer

Organophosphate Poisoning

SSx Abdominal Pain cough, drooling

Dx serum pseudocholinesterase and erythrocyte cholinesterase levels

Why? ↓ activate Ach receptor

Tx Supportive decontamination
Atropine Pralidoxime
(inhibits Muscarinic receptor) (reactivates cholinesterase)

D - Diarrhea
U - urination
M - miosis
D - Bronchorrhea
B - Bronchospasm
E - Emesis
L - lacrimation
S - salivation

BOTULISM

Sx Droopy eyelids blurred vision difficulty swallowing, speaking
late: paralysis of diaphragm.

Infant Floppy baby. weak cry
Note: the endospore doesn't cause Dx the exotoxin produced does.

Symmetric Descending Paralysis/Flaccid

No fever, Symmetric Necrosis
No sensory effects
Blurred vision
Gram (+) Rod
Acid fast Stain
Non-communicable person to person
Head resulting in necrosis

Why? enters mouth bypasses stomach attaches to small intestine.
Attacks to motor Nerves block Ach Transmission
toxin A-B Toxin (presynaptic)
B - binds to motor receptors
A - inactivates release of Neurotransmitters

LMNL
↓reflexia
hypotonia

EXAM:
↓DTR

Tx Equine anti-toxin
Diphenhydramine
epinephrine

Infant: spores get ingested in GI b/c kids don't have good bacteria to fight it. Produce Neurotoxin

From where: Soils rivers sea water
Resuscitation - Wound - Spores get into open wound
Food Borne (MC) - ingest preformed toxin
Infant - ingests spores
Inhalation - Bioterrorism, Soil/Gardening plants

DDx Myasthenia via a nml Tensilon Test

Dx by culturing toxin from Stool, Serum, or food

Polymyositis

progressive/Gradual proximal muscle weakness of unknown etology. Invasion of immune system inflammatory cells into muscle fibers. Non-painful

CD8 in muscle biopsy
endomysial inflammation
(Dermato. is Perimysial)

Dx Serum CK - 4-5-50x (if > 100x then Not Polymyositis)
Anti-Jo (20-40%)

Tx Prednisone 4-8 weeks (then Taper)
IV - Methotrexate.

EXAM nml Sensory, nml DTR
(No skin involvement)
CD8 T-cells mediate Damage in Poly.
CD4 T-cells and antibodies mediate in Dermato.

Dermatomyositis

nml sensory
nml DTR
anti-Jo1

CD4 in muscle biopsy
ages 5-15 40-60 yrs.
progressive gradual symmetrical weakness
Sx: Dysphagia (upper ½ striated) fever, weight loss, contracture
Heliotrope Rash - purple discoloration of upper eyelids with edema
Gottrons papules - raised violaceous rash over PIP and MCP
inflam. Raynauds.

Dx Rash, Gottrons DDx from Polymyositis
↑CK

Tx same as Polymyositis

Note also cancer (ovarian, breast, lung, stomach, bladder) tumors

Corticosteroids

Possess both glucocorticoid and mineral corticoid to some extent
Glucocorticoids - convert protein to carbs/gluconeogenesis
↑Urinary Ca^{2+} → ↑ Kidney stones.
Mineralcorticoids | Note ↑ Na^+ ↓ K^+ Theory of ↑ K^+