RENAL

Na | CL | BUN — Glu
K | CO_2 | Cr

NH_3 (Ammonia)
↓
Liver — made into urea
(urea) NH_2 goes into blood
NH_2
↓
BUN → to Kidney

Acetyl CoA (need $2C^{'s}$) → Krebs cycle → ATP

Krebs cycle

3 sources

① Carbs 6 carbon chains
6C → 2 x 3C → 2C → Krebs
CO_2

② Lipids
Betaoxidation chops into $2C^s$
HO

③ Proteins (amino acids)
N-C-C-N-C-C
proteases chop up N-C-C
N Ammonia (Toxic) NH_3

What ↑urea?
- Burns (↑protein breakdown)
- Steroids (↑catabolic state)
- Tetracycline

↓BUN
Liver failure

Note Esophaged Varices (Dysfunctional Liver)
Blood trying to return to heart.
∴ you have bleeding into digestive Tract
Blood being digested → ↑NH_3
If GI bleed not from Liver failure (↑BUN)

Creatinine
comes from muscle breakdown
↓GFR by 50% to ↑Cr
↓Cr w/ Muscle Wasting

TMP
cimetidine
(block Cr secretion)

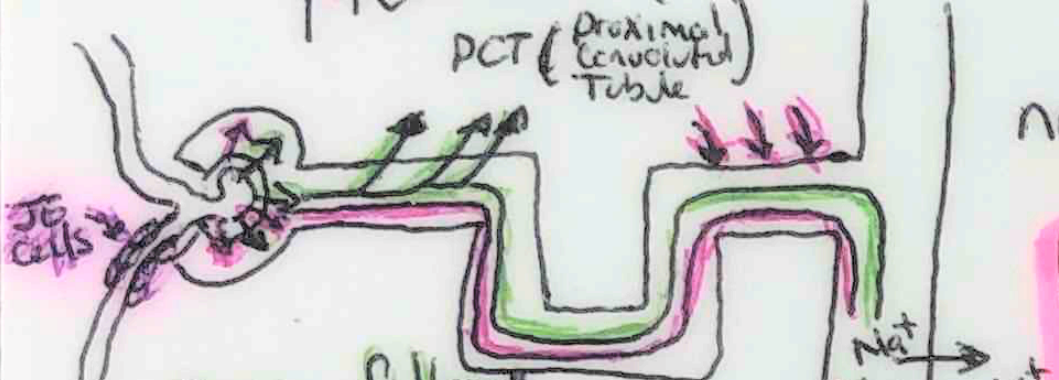

BUN = filtered reabsorbed

Cr = filtered, secreted

NML $\frac{BUN}{Cr} = \frac{15}{1}$

GFR affects BUN = If slow (low), the BUN is more likely to be reabsorbed (∴ release of aldosterone)

JG cells = afferent arteriole → secrete renin in response to ↓renal BP, ↓Na^+ delivery to Distal Tubule, and ↑sympathetic Tone

Pre-Renal

↓blood to Kidney
(↓C.O., Hypovolemia, Renal Artery Stenosis)

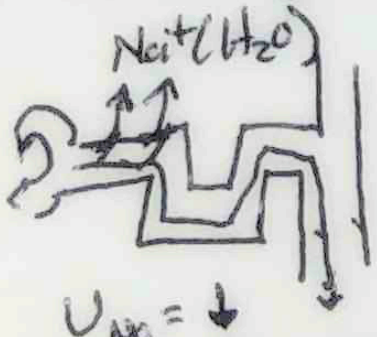

U_{Na} = ↓
U_{osm} = ↑ (conc.)
low flow = $\frac{↑↑BUN}{↑Cr} = \frac{20}{1}$

Renal

Issue w/ Tubular Cells
(Aminoglycosides, NSAIDs, ACE, ATN (↓O_2))

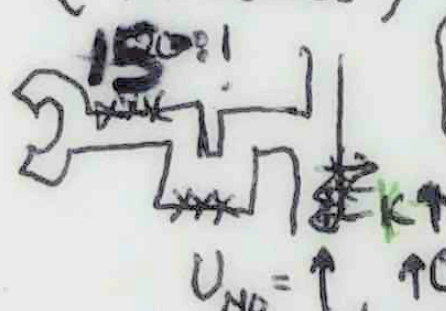

U_{Na} = ↑, ↑Cr
U_{osm} = ↓ 1.010
⇓
Intrarenal Causes x3

Post-Renal

(Prostate Issue, Cervical Cancer, Tumors)

early on looks like pre-renal (FENa<1%)
later - Renal.
Do U/S to see if Kidneys enlarge

① Acute Interstitial Nephritis

b/n Tubules
"Eosinophilia"
NSAIDs, PCN, Diuretics
SS_x: Oliguria, Fever, Rash
days to weeks after Drugs
Resolves after cessation.



② MC Acute Tubular Necrosis

"Brown Granular casts"



cells die and plug up Tubule.
↓GFR
(back pressure)

2 causes
- Ischemia — $\frac{BUN}{Cr}$ = 15
- Nephrotic — Aminoglycosides, Ethylene glycol, Radioactive Dye, Urate (Tumor lysis)

Hyperkalemia

③ Renal Papillary Necrosis

gross hematuria, flank pain
- necrosis of papillae
causes long Term aspirin, DM, Sickle cell Trait or Dx, severe pyelonephritis

Congenital

Horseshoe Kidney = caught in inferior mesenteric Artery.

Renal Agenesis - uni, or bi.
unilateral - hyperfiltration of existing Kidney (leads to renal failure)
Bilateral - oligohydramnios
incompatible w/ life.
1) lung hypoplasia
2) Flat facies
3) low set ears
4) developmental Defects
} Potters Sequence.

Dysplastic Kidney = "Beyond repair"
Non inherited - low risk of passing on to next child.
cysts in Kidney (uni or bi)

Medullary Cystic D_x
- inherited (A.D.)
- cysts in medullary collecting duct
- Parenchymal / Fibrosis results in shrunken Kidney (↑ renal failure)

Polycystic Kidney D_x

inherited, bilateral enlarged Kidney with cysts in Cortex and medulla.

Autosomal Recessive (ARPKD)
Juvenille
- worsening renal failure w/ HTN
- Potters Sequence
- A/w congenital Hepatic fibrosis and Hepatic Cysts
(SS_x Portal HTN)

Autosomal Dominant (ADPKD)
(young Adult)
HTN, hematuria
renal failure
APKD, $APKD_2$
cysts develop over time
(↑plasma renin)
a/w Berry Aneurysm, Hepatic Cyst, MVP.



H&E staining
E.M. = Electron Microscopy
I.F. = Immunofluorescence

Nephrotic >3.5gm/day

SS_x:
- Hypoalbuminemia (↓oncotic pressure) pitting edema.
- Hypogammaglobulinemia (↑infection)
- Hypercoagulable State (↓ATIII)
ATIII normally destroys thrombin
- Hyperlipidemia

Minimal Change D_x

A/w Hodgkins (excess Cytokines)
or Idiopathic
SS_x fever chills, nightsweats



effacement of foot processes
H&E: nml
E.M.: effacement of foot processes
IF: negative

loose albumin but not immunoglobulin

T_x steroids (Knocks out cytokines)
if doesn't respond, turns into FSGN.

Focal Segmental Glomerulonephritis FSGN

MCC Nephrotic Syndrome in Hispanics, HIV(+), Heroin users, Sickle cell D_x
H&E: Focal and Segmental Sclerosis
E.M: Effacement of foot Processes
IF: Negative
Poor response to steroids.
Progresses to renal failure.

Membranous Nephropathy

→ means "Immune complex"

MCC Caucasian
Idiopathic a/w HepB, HepC, SLE, Solid Tumors, Drugs (NSAIDs, PCN)



The BM lays on top of Immune Deposits

H&E: Thick glomerular BM.
EM: Spike and Dome Subepithelial Deposits
IF: presents "Granular" at level of Podocyte (epithelium)
Tx Poor response to Steroids

Membrano Proliferative Glomerulonephritis

Type II can be Nephrotic or Nephritic



H&E = Thick BM
E.M: Tram Track
IF: Granular

Based on site of deposit

Type I



Subendothelia
a/w HepB, HepC.

Type II



Pts have C3 nephritic factor. autoantibody

C3 → C3A, C3B
↑
C3 convertase
(usually quick on and off but C3 nephritic factor the C3 convertase is not turned off.
"Stabilizes C3 convertase"
Overactivation of complement
↓Serum C3

Diabetes Mellitus

nonenzymatic glycosylation of BM results in hyaline arteriosclerosis.
Efferent arteriole most affected



sclerosis of mesangium will lead to nephrotic syndrome.
Kimmelstiel-wilson nodules
Tx use ACE Inh.

Systemic Amyloidosis

Kidneys are MC affected organ.
(amyloid in mesangium)
Apple green birefringence
Amyloid = abnormal protein from bone marrow that deposits into tissue with Diseases.

Nephritic Syndrome

(Driven by deposition of Immune Complexes)
↓
activates complement and C5a which attracts Neutrophils which initiates damage

< 3.5 gm/day
- Bleeding, Oliguria
- Salt retention, periorbital edema
  HTN
- RBC casts


RBC's stuck
"Casted"

PSGN

- carries M-Protein
- occurs 2-3 weeks after infection
- Cola-colored urine (Hematuria)

H&E: Hypercellular, inflamed glomeruli (b/c immune deposits)
IF: Granular
EM: Subepithelial "Humps"

Tx Supportive
rarely in adults <25% leads to RPGN
" " child <1% leads to renal failure

RPGN

Nephritic syndrome that progresses to renal failure in weeks to months.
"Crescents in Bowmans Space" made of fibrin and macrophages

3 options

linear IM
Goodpastures

IgG antibody against BM
cough, Kidney

IF: Granular
PSGN or Diffuse Proliferative Glomerulonephritis
(MC renal Dx in Lupus)
Subendothelial

IF: negative
Stain
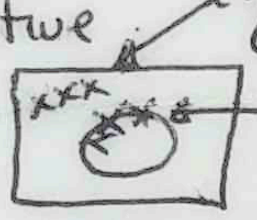

peri cytoplasmic C-ANCA
peri-nuclear P-ANCA

C-ANCA Wegeners

Sinus
lungs
Kidney

P-ANCA
Microscopic polyangiitis and Churg-Strauss
- granulomatous inflammation
- eosinophilia
- Asthma.



IgA Nephropathy

Deposition in Mesangium
usually childhood
(RBC casts)
usually follows mucosal infection
(↑IgA due to mucosal inf.)

Alports Syndrome

Type IV Collagen
X-linked: you will see Family Hx
Cant See, Cant Pee, Cant Hear
Ocular Disturbance, Hematuria, Sensoneural Hearing loss.

UTI's

UA - cloudy urine
Dipstick = Nitrates ⇒ Nitrites
ascending infection
Culture: >100K CFU
#1: E.Coli

Sterile Pyuria Pyuria (>10 wbc/hpf) with negative culture
suggests: chlamydia or Neisseria Gonorrhea.

Pyelonephritis ascending, vesicoureteral reflux
Fever, Flank Pain, WBC casts   MCC: E.Coli

Chronic Pyelonephritis leads to scarring (Interstitial fibrosis)
Due to vesicoureteral reflux (or obstruction) "Waxy Casts" in urine

Nephrolithiasis

Tx

① Calcium Oxalate or Calcium phosphate
Due to ↑Ca^{2+} in urine.
seen in Chrons Dx
(Small bowel damage results in ↑resorption of oxalate which binds calcium)
HCTZ

② Ammonium Magnesium phosphate
Alkaline urine (Proteus or Klebsiella)
Staghorn Calculi ⇒ Surgery
eradicate pathogen

③ Uric Acid
Radiolucent a/w low urine volume, acidic pH.
MC w/ Gout, hyperuricemia
Hydration and alkalinization of urine (Potassium bicarbonate)
allopurinol (gout)

④ Cysteine
Rare. MC children
may form Staghorn Calculi
a/w cystinuria (genetic defect of tubules)

Chronic Renal Failure

- uremia - ↑nitrogenous waste
- Salt and H_2O retention (HTN)

Hyperkalemia
metabolic Acidosis
Anemia due to ↓erythropoietin
- hypocalcemia (↓1α-hydroxylase)
- Renal Osteodystrophy

Tx Dialysis
↓
Shrunken Kidney at risk for RCC.

↓BP (JG cells)
↓Na+ delivery (MD cells)
↑sympathetic Tone (β₁)
↓
Renin
Angiotensinogen → angiotensin I → Angiotensin II

made in Liver

Lungs + Kidneys
ACE ⊣ Bradykinin

(powerful vasoconstrictor)
↑aldosterone
↑thirst (Hypothal)
↑ADH

Note: with ADH
Blood Volume takes precedent over Osmolarity

Shifts K^+ in cell
1) Insulin
2) Beta agonists
3) Alkalosis (K/H exchange)
4) Hypoosmolality

Shifts K^+ out (cause Hyperkalemia)
1) Insulin deficiency
2) β-antagonists
3) Acidosis (Severe exercise)
4) Hyperosmolality
5) Digitalis (blocks ATPase)
6) Cell lysis

Drugs

Mannitol Osmotic Diuretic
Used: shock, drug overdose
↑intracranial pressure
Do not use in CHF, anuria

Acetazolamide Carbonic anhydrase inhibitor (↓Bicarb)
uses: altitude sickness, metabolic alkalosis
glaucoma.

Furosemide Sulfonamide
inhibits Na/K/2Cl of thick ascending loop
stimulate PGE release (vasodilatory on afferent arteriole)
inhibited by NSAIDs, ↑Ca^{2+} excretion
Toxicity: ototoxic, Hypokalemia, Gout
rev. interstitial Nephritis

Ethacrynic Acid not sulfonamide
Ototoxic - non reversible

HCTZ HyperGLUC Glycemia Lipidemia Uricemia; Calcemia
Sulfa allergy.

Lower urinary Tract Carcinoma

Urothelial (Transitional Cell) Carcinoma
#1 risk factor is smoking
Painless Hematuria

Papillary Growth

Squamous Cell Carcinoma
usually involves bladder
a/w chronic cystitis
"Schistosoma Hematobium" (embeds w/n bladder wall)
- Egyptian, middle eastern male.

Adenocarcinoma malignant proliferation of glands
from Urachal remnant - Dome of bladder

Renal Tumors

Angiomyolipoma Tumor of blood vessels, Smooth MM, and adipose Tissue a/w Tuberous Sclerosis

Renal Cell Carcinoma Hematuria, palpable flank mass.
Fever, weight loss.
a/w left side Varicocele.
M.C. is Clear Cell Type.
loss of VHL tumor suppressor gene
(↑risk of hemangioblastoma of Cerebellum and RCC)

Wilms Tumor MC Malignant renal Tumor in children.
SSx: unilateral Flank mass w/ Hematuria and HTN
most are sporadic but seen in WAGR (Aniridia, Genital Abnormality, mental Retardation